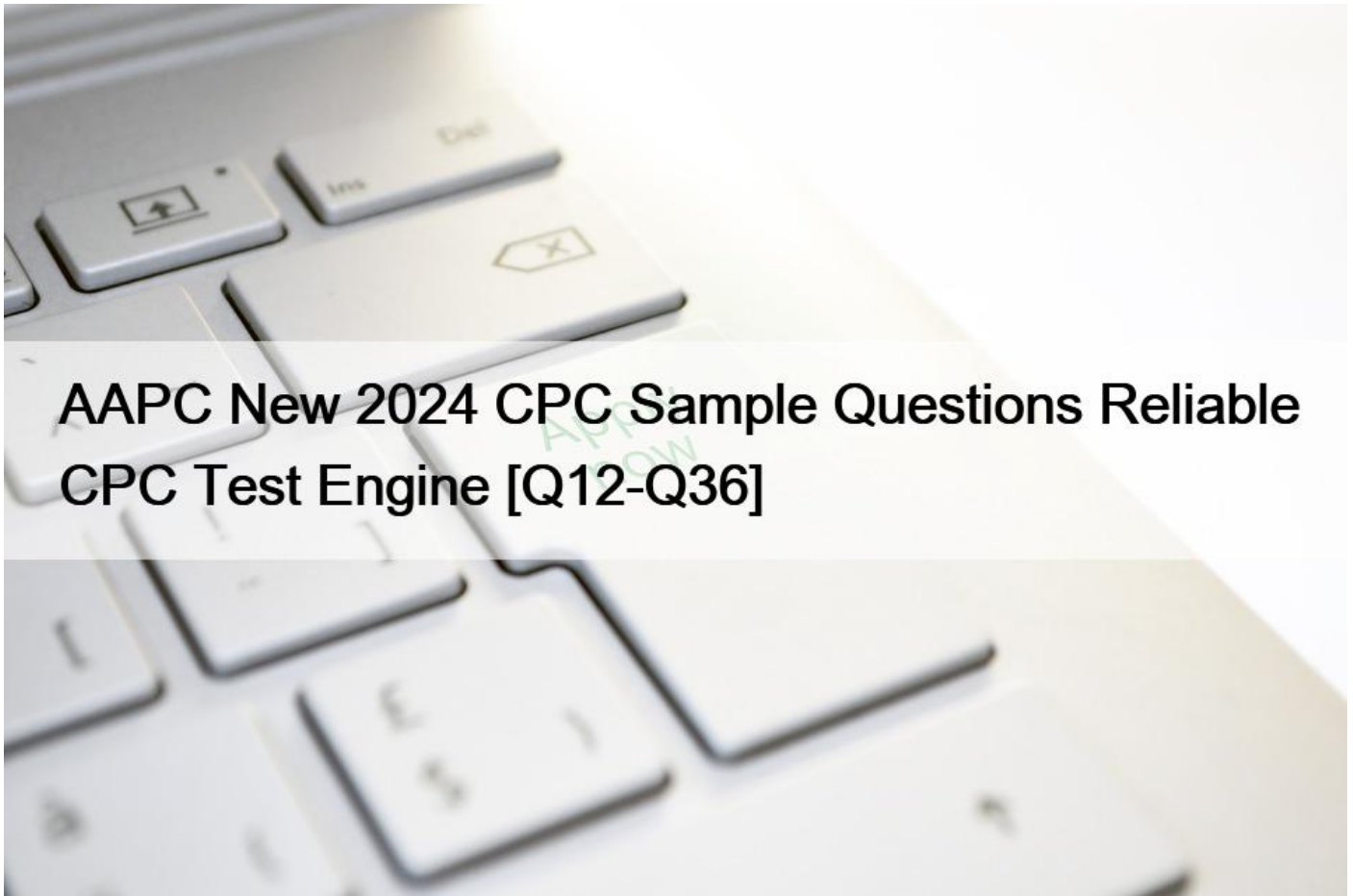


AAPC New 2024 CPC Sample Questions Reliable CPC Test Engine [Q12-Q36]



AAPC New 2024 CPC Sample Questions Reliable CPC Test Engine
Feel AAPC CPC Dumps PDF Will likely be The best Option

AAPC CPC Exam Syllabus Topics:

TopicDetailsTopic 1- Provide practical application of coding operative reports and evaluation and management services- Understand and apply the official ICD-10-CM coding guidelinesTopic 2- Apply coding conventions when assigning diagnoses and procedure codes- Identify the purpose of the CPT®, ICD-10-CM, and HCPCS Level II code booksTopic 3- Code a wide variety of patient services using CPT®, ICD-10-CM, and HCPCS Level II codes- Explain the determination of the levels of E- M servicesTopic 4- Identify the information in appendices of the CPT® code book- List the major features of HCPCS Level II codes

NEW QUESTION 12

The CPT code book provides full descriptions of medical procedures, although some descriptions require the use of a semicolon (;) to distinguish among closely related procedures.

What is the full description of CPT code 69644?

- * Tympanoplasty with mastoidectomy (including canalplasty, middle ear surgery, tympanic membrane repair); with intact or reconstructed canal wall, with ossicular chain reconstruction
- * Without ossicular chain reconstruction with intact or reconstructed canal wall, with ossicular chain reconstruction
- * With intact or reconstructed canal wall with ossicular chain reconstruction
- * Tympanoplasty with mastoidectomy (including canalplasty, middle ear surgery, tympanic membrane repair); without ossicular chain reconstruction with intact or reconstructed canal wall, with ossicular chain reconstruction

NEW QUESTION 13

A 5-year-old is brought to the QuickCare in the ED to repair two lacerations: a 3 cm laceration on her right arm and 2 cm laceration on her nose. Her arm is repaired with a simple one-layer closure with sutures. Her nose is repaired with a simple repair using tissue adhesive, 2-cyanoacrylate.

How are the repairs reported?

- * 12013
- * 12032, 12041-59
- * 12002
- * 12002, 12011-59

NEW QUESTION 14

A 6-French sheath and catheter is placed into the coronary artery and is advanced to the left side of the heart into the ventricle. Ventriculography is performed using power injection of contrast agent. Pressures in the left heart are obtained. The coronary arteries are also selected and imaged.

What CPT code is reported?

- * 93460
- * 93454
- * 93456
- * 93458

NEW QUESTION 15

A patient underwent a cystourethroscopy with a pyeloscopy using lithotripsy to break up the ureteral calculus. An indwelling stent was also inserted during the same operative session on the same side. This service was performed in the outpatient hospital surgery center.

What CPT coding reported?

- * 52352, 52332-51
- * 52325, 52332-51
- * 52353, 52332-51
- * 52356

NEW QUESTION 16

An elderly patient comes into the emergency department (ED) with shortness of breath. An ECG is performed. The final diagnosis at discharge is impending myocardial infarction.

According to ICD-10-CM guidelines, how is this reported?

- * I20.0
- * R06.02
- * I20.0, R06.02
- * I21.3, R06.02

NEW QUESTION 17

View MR 003396

MR 003396

Operative Report

Preoperative Diagnosis: Acute MI, severe left main arteriosclerotic coronary artery disease Postoperative Diagnosis: Acute MI, severe left main arteriosclerotic coronary artery disease Procedure Performed: Placement of an intra-aortic balloon pump (IABP) right common femoral artery Description of Procedure: Patient's right groin was prepped and draped in the usual sterile fashion. Right common femoral artery is found, and an incision is made over the artery exposing it. The artery is opened transversely, and the tip of the balloon catheter was placed in the right common femoral artery. The balloon pump had good waveform. The balloon pump catheter is secured to his skin after local anesthesia of 2 cc of 1% Xylocaine is used to numb the area. The balloon pump is secured with a 0-silk suture. The patient has sterile dressing placed. The patient tolerated the procedure. There were no complications.

What CPT coding is reported for this case?

- * 33975
- * 33967
- * 33970
- * 33973

NEW QUESTION 18

Which statement regarding lesion excision is TRUE?

- * Lesion excision codes include removal of a lesion, with margins, and simple (nonlayered) closure when performed
- * Lesion excision codes are selected by measuring the greatest clinical diameter of a lesion excluding the margins required to complete the excision
- * Lesion excision codes include removal of a lesion, with margins, and intermediate closure when performed
- * Lesion excision codes include removal of a lesion with margins, and complex closure when performed

NEW QUESTION 19

A patient with a history of chronic venous embolism in the inferior vena cava has a radiographic study to visualize any abnormalities. In outpatient surgery the physician accesses the subclavian vein and the catheter is advanced to the inferior vena cava for injection and imaging. The supervision and interpretation of the images is performed by the physician.

What codes are reported for this procedure?

- * 36000, 75825-26
- * 36010, 75827-26
- * 36010, 75825-26
- * 36000, 75827-26

NEW QUESTION 20

View MR 099405

MR 099405

CC: Shortness of breath

HPI: 16-year-old female comes into the ED for shortness of breath for the last two days. She is an asthmatic.

Current medications being used to treat symptoms is Advair, which is not working and breathing is getting worse. Does not feel that Advair has been helping. Patient tried Albuterol for persistent coughing, is not helping. Coughing 10-15 minutes at a time. Patient has used the Albuterol 3x in the last 16 hrs. ED physician admits her to observation status.

ROS: No fever, no headache. No purulent discharge from the eyes. No earache. No nasal discharge or sore throat. No swollen glands in the neck. No palpitations. Dyspnea and cough. Some chest pain. No nausea or vomiting. No abdominal pain, diarrhea, or constipation.

PMH: Asthma

SH: Lives with both parents.

FH: Family hx of asthma, paternal side

ALLERGIES: PCN-200 CAPS. Allergies have been reviewed with child's family and no changes reported.

PE: General appearance: normal, alert. Talks in sentences. Pink lips and cheeks. Oriented. Well developed. Well nourished. Well hydrated.

Eyes: normal. External eye: no hyperemia of the conjunctiva. No discharge from the conjunctiva Ears: general/bilateral. TM: normal. Nose: rhinorrhea. Pharynx/Oropharynx: normal. Neck: normal.

Lymph nodes: normal.

Lungs: before Albuterol neb, mode air entry b/l. No rales, rhonchi or wheezes. After Albuterol neb. improvement of air entry b/l. Respiratory movements were normal. No intercostals inspiratory retraction was observed.

Cardiovascular system: normal. Heart rate and rhythm normal. Heart sounds normal. No murmurs were heard.

GI: abdomen normal with no tenderness or masses. Normal bowel sounds. No hepatosplenomegaly Skin: normal warm and dry. Pink well perfused Musculoskeletal system patient indicates lower to mid back pain when she lies down on her back and when she rolls over. No CVA tenderness.

Assessment: Asthma, acute exacerbation

Plan: Will keep her in observation overnight. Will administer oral steroids and breathing treatment. CXR ordered and to be taken in the morning.

What E/M code is reported?

* 99221

* 99284

- * 99285
- * 99222

NEW QUESTION 21

A patient suffers a ruptured infrarenal abdominal aortic aneurysm requiring emergent endovascular repair. An aorto-aortic tube endograft is positioned in the aorta and a balloon dilation is performed at the proximal and distal seal zones of the endograft. The balloon angioplasty is performed for endoleak treatment.

What CPT code does the vascular surgeon use to report the procedure?

- * 34702
- * 34701
- * 34707
- * 34708

NEW QUESTION 22

A surgeon performs midface LeFort I reconstruction on a patient's facial bones to correct a congenital deformity. The reconstruction is performed in two pieces in moving the upper jawbone forward and repositioning the teeth of the maxilla of the mid face.

What CPT code is reported?

- * 21146
- * 21141
- * 21142
- * 21145

NEW QUESTION 23

This 27-year-old male has morbid obesity with a BMI of 45 due to a high calorie diet. He has decided to have an open Roux-en-Y gastric bypass. The patient is brought to the operating room and placed in supine position. A midline abdominal incision is made. The stomach is mobilized, and the proximal stomach is divided and stapled creating a small proximal pouch in continuity with the esophagus. A short limb of the proximal bowel of 155 cm is divided. It is brought up and anastomosed to the gastric pouch. The other end of the divided bowel is connected back into the distal small bowel to the short limb's gastric anastomosis to restore intestinal continuity. The abdominal incision is closed.

What are the procedure and diagnosis codes for this encounter?

- * 43847, E66.01, Z68.42
- * 43644, E66.01, Z68.43
- * 43847, E66.9, Z68.42
- * 43645, E66.8, Z68.42

NEW QUESTION 24

According to the Application of Cast and Strapping CPT guidelines, what is reported when an orthopedic provider performs initial fracture care treatment for a closed scaphoid fracture of the wrist, applies a short arm cast, and the patient will be returning for subsequent fracture care?

- * 25622
- * 29075
- * 25622, 29075

* 29075-22

NEW QUESTION 25

A couple presents to the freestanding fertility clinic to start in vitro fertilization. Under radiologic guidance, an aspiration needle is inserted (by aid of a superimposed guiding-line) puncturing the ovary and preovulatory follicle and withdrawing fluid from the follicle containing the egg.

What is the correct CPT code for this procedure?

- * 58976
- * 58974
- * 58999
- * 58970

NEW QUESTION 26

A patient with empyema requires a Schede thoracoplasty.

What CPT code is reported for this procedure?

- * 32906
- * 32999
- * 32905
- * 32900

NEW QUESTION 27

An incision is made in the scalp, a craniectomy is performed to access the area where electrodes are present. The electrodes are removed. The surgical wound is closed.

What procedure code is reported?

- * 61850
- * 61880
- * 61535
- * 61860

NEW QUESTION 28

A catheter was placed into the abdominal aorta via the right common femoral artery access. An abdominal aortography was performed. The right and left renal artery were adequately visualized. The catheter was used to selectively catheterize the right and left renal artery. Selective right and left renal angiography were then performed, demonstrating a widely patent right and left renal artery.

What CPT coding is reported?

- * 36251
- * 36252
- * 36253, 75625-26
- * 36252, 75625-26

NEW QUESTION 29

A physician prescribes carbamazepine to treat a patient with epileptic seizures. After six months, the physician performs a therapeutic drug test to monitor the total level of the drug in the patient.

What CPT and ICD-10-CM coding is used for the six month-evaluation?

- * 80156, R56.9
- * 80157, R56.9
- * 80157, G40.909
- * 80156, G40.909

NEW QUESTION 30

Mr. Roland has difficulty breathing and congestion with a productive cough. The physician takes frontal and lateral view chest X-rays in the office (the equipment is owned by the physician group). The physician reads the X-rays and determines a diagnosis of walking pneumonia. The physician's interpretation is placed in the patient's chart.

How does the physician bill for the chest X-ray?

- * 71046-26
- * 71046-26-TC
- * 71046-TC
- * 71046

NEW QUESTION 31

The mediastinum is:

- * A location in the chest, bounded by the sternum, diaphragm, and lungs
- * A small endocrine organ behind the heart
- * A part of the lymphatic system
- * Both the heart and lungs

NEW QUESTION 32

A 55-year-old patient was recently diagnosed with an enlarged goiter. It has been two years since her last visit to the endocrinologist. A new doctor in the exact same specialty group will be examining her. The physician performs a medically appropriate history and exam. The provider reviewed the TSH results and ultrasound. The provider orders a fine needle aspiration biopsy which is a minor procedure.

What E/M code is reported?

- * 99202
- * 99214
- * 99205
- * 99213

NEW QUESTION 33

The human shoulder is made of which three bones?

- * Olecranon, radius, ulna
- * Carpal, radius, humerus
- * Metatarsal, tibia, navicular
- * Clavicle, scapula, humerus

NEW QUESTION 34

A complete cardiac MRI for morphology and function without contrast, followed by contrast with four additional sequences and stress imaging, is performed on a patient with systolic left ventricular congestive heart failure and premature ventricular contractions.

What CPT and ICD-10-CM codes are reported?

- * 75557, 75559, I50.1, I49.1
- * 75561, 75563, I50.1, I49.1
- * 75563, I50.20, I49.3
- * 75559, I50.20, I49.3

NEW QUESTION 35

A patient is diagnosed with diabetic polyneuropathy.

Using ICD-10-CM coding guidelines, what ICD-10-CM coding is reported?

- * E10.42
- * E11.9, G62.9
- * E10.9, G62.9
- * E11.42

NEW QUESTION 36

View MR 006399

MR 006399

Operative Report

Preoperative Diagnosis: Chronic otitis media in the right ear

Postoperative Diagnosis: Chronic otitis media in the right ear

Procedure: Eustachian tube inflation

Anesthesia: General

Blood Loss: Minimal

Findings: Serous mucoid fluid

Complications: None

Indications: The patient is a 2-year-old who presented to the office with chronic otitis media refractory to medical management. The treatment will be eustachian tube inflation to remove the fluid. Risks, benefits, and alternatives were reviewed with the family, which include general anesthetic, bleeding, infection, tympanic membrane perforation, routine tubes, and need for additional surgery. The family understood these risks and signed the appropriate consent form.

Procedure in Detail: After the patient was properly identified, he was brought into the operating room and placed supine. The patient

was prepped and draped in the usual fashion. General anesthesia was administered via inhalation mask, and after adequate sedation was achieved, a medium-sized speculum was placed in the right ear and cerumen was removed atraumatically using instrument with operative microscope. The tube is dilated, an incision is made to the tympanum and thick mucoïd fluid was suctioned. The patient was awakened after having tolerated the procedure well and taken to the recovery room in stable condition.

What CPT coding is reported for this case?

- * 69420-RT
- * 69436-RT
- * 69433-RT
- * 69421-RT

Use Valid New CPC Test Notes & CPC Valid Exam Guide:

<https://www.examlabs.com/AAPC/Certified-Professional-Coder/best-CPC-exam-dumps.html>